



## Towards Smart-Phone Image-Based Automated Diabetic Retinopathy Diagnostic System in Sub-Saharan Africa: The System's Security Perspective.

**Temitope Mapayi<sup>1</sup>, Jules R. Tapamo<sup>2</sup>, Adedayo O. Adio<sup>3</sup> & Moses O. Olaifa<sup>4</sup>**

<sup>1</sup>Department of Electrical Engineering, Mangosuthu University of Technology, Umlazi, Durban, South Africa.

<sup>2</sup>School of Engineering, University of KwaZulu-Natal, Durban, 4041, South Africa;

<sup>3</sup>Department of Ophthalmology, University of Port Harcourt, Port Harcourt, Nigeria.

<sup>4</sup>Department of Computer Systems Engineering, Tshwane University of Technology, Pretoria, South Africa

**Email Address:** [mapayi.temitope@mut.ac.za](mailto:mapayi.temitope@mut.ac.za); [tapamoj@ukzn.ac.za](mailto:tapamoj@ukzn.ac.za); [drdayoadio@yahoo.com](mailto:drdayoadio@yahoo.com); [olaifamo@tut.ac.za](mailto:olaifamo@tut.ac.za)

**Phone Number:** +2749260172

### ABSTRACT

Medical imaging has become a significant field of research due to the advances in the hardware and software resources used for the acquisition, processing and storage of the images. With the help of several imaging modalities, physicians are better informed with detailed knowledge of healthy or diseased anatomy for efficient diagnosis, patient monitoring and treatment as well as clinical studies. In the face of the global prevalence of Diabetic retinopathy (DR), the cases of vision loss and blindness tend to increase in the absence of efficient detection and management approaches of the disease in Sub-Saharan Africa. The families, communities and countries affected by these epidemics are also likely to suffer serious economic setbacks caused by the financial burden, reduced-earnings and reduced-productivity due to visual impairment and blindness. Smart-phone image-based diagnostic systems using automated approach has the potential to assist trained field workers in attending to larger number of people with diabetes in the areas where there are no ophthalmologists while patients who need further medical care can be referred to ophthalmologists at an early stage rather than advanced stage of the DR. This paper presents a secured framework of a smart-phone image-based automated DR diagnostic system to improve the management of DR in Sub-Saharan Africa.

**Keywords:** Automated, Diabetic retinopathy, Diagnostic & Secured.

### ISTEAMS Cross-Border Conference Proceedings Paper Citation Format

Temitope, Mapayi, Jules R. Tapamo, Adedayo O. Adio & Moses O. Olaifa (2017): Towards Smart-Phone Image-Based Automated Diabetic Retinopathy Diagnostic System in Sub-Saharan Africa: The System's Security Perspective. Proceedings of the 9th iSTEAMS Multidisciplinary Conference, University of Ghana, Legon, Accra, Ghana. Pp 1-8

### 1. BACKGROUND TO THE STUDY

Diabetes has become a growing menace worldwide [1]. According to the international diabetes federation (IDF) [2], 382 million people were affected by diabetes worldwide in 2013. There has also been a projection of 55% increment in the number of people living with diabetes globally between the years 2013 and 2035 by IDF, with 96% increment in the Middle East and North Africa, 71% in South-East Asia, 60% in South and Central America, 46% in Western Pacific, 37% in North America and Caribbean, 22% in Europe and the maximum increment of 109% in Africa. According to the projection, the number of people living with diabetes will have increased from 382 million to 592 million people by the year 2035.

Diabetic retinopathy (DR), an eye disease secondary to diabetes, is a major cause of visual loss and blindness worldwide [3]. Recently, 35% of diabetic patients have been estimated to be living with DR worldwide [4]. There are basically two stages of DR: the early stage, which is the non-proliferative DR and the advanced stage, which is the proliferative DR [5]. Although DR remains symptomless in the early stages [6], retinal vessels are the predominant damage targets of diabetes at these early stages. Different abnormalities such as changes in vessel shape, branching pattern, width, tortuosity, or the appearance of retinal lesions, can be associated with the presence of retinopathies [7]. Regular retinal examinations of the diabetic patients can help in the early detection of DR and the significant reduction of the cases of blindness [8].



Mbanya and Sobngwi [9] showed that 16–55% of people with diabetes have DR while retinopathy accounted for 32% in [10]. A study conducted by an eye care centre in Cape Town revealed that 55% of 300 randomly selected black patients were said to be diagnosed of proliferative DR, while 16% were diagnosed of pre-proliferative DR [11]. A high prevalence of retinopathy in 56% of blacks South Africans and 45% of Indians South Africans were presented in [12]. A study from Malawi showed that 50% of 357 diabetic patients examined had retinopathy with 7% diagnosed with proliferation, 26% diagnosed with maculopathy, and 29% diagnosed with sight-threatening disease [13]. Rotimi et al. investigated the prevalence and risk factors for cataracts and diabetic retinopathy in 840 patients from Nigeria and Ghana. The study showed the prevalence of DR was 18% [14]. As DR continues to be one of the major causes of visual loss and blindness worldwide, the early detection and management of the disease will help in the significant reduction of blindness cases in Africa.

Retinal fundus imaging in ophthalmology has been of great use in medical diagnosis and progression monitoring of DR [18]. Although several digital imaging modalities are used in ophthalmology, coloured fundus photography remains an important retinal imaging modality due to its safety and cost-effective mode of retinal abnormalities documentation [19].

There are some important anatomic structures in the human retina (See Figure 1(a)). The robust segmentation of these different anatomic structures of the retina is necessary for a reliable characterisation of healthy or diseased retina. Ophthalmologists, with the help of detected vessel network and other anatomic structures of the retinal, focus on retinal vessel feature analysis during the diagnosis of the disease [20]. Manual detection and analysis of the retinal vessels has been a very tedious and time consuming task that requires about two hours to detect vessels in each retinal image [21] and requires trained and skilled personnel who are often scarce [22] [23]. However, with the help of automatic segmentation and analysis of the anatomic structures, ophthalmologist can now diagnose, monitor the progression and efficiently manage the disease as the required time to detect and analyse the different anatomic structures is drastically reduced [24].

Image segmentation, which is an important step in image analysis, involves the partitioning of a digital image into multiple regions with uniform and homogeneous attributes such as intensity, colour or texture [25]. It is used to locate and detect boundaries and objects of interest in images. Several automated techniques of segmentation have successfully been used to detect different anatomic features as well as retinopathy features in retinal images [26] (See Figure 1(b) & 1(c)).

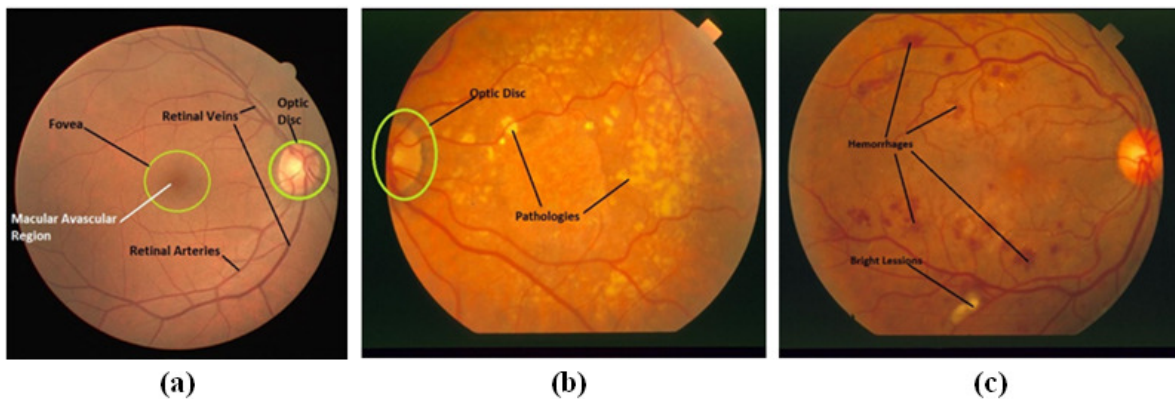


Figure 1: Retinal Image Anatomic Structures

Several techniques have been implemented for the automatic detection of optic disk [21] [22]. Pathologies such as microaneurysms [23] with exudates and cotton wool spot [24] have been automatically detected in retinal images. The segmentation of the vessel network has also been identified to be of help in ophthalmology to focus on retinal vessel morphological features which are often early indicators of DR [25] as they help in the diagnosis and progress monitoring of the DR when the vessel morphological features are analysed.

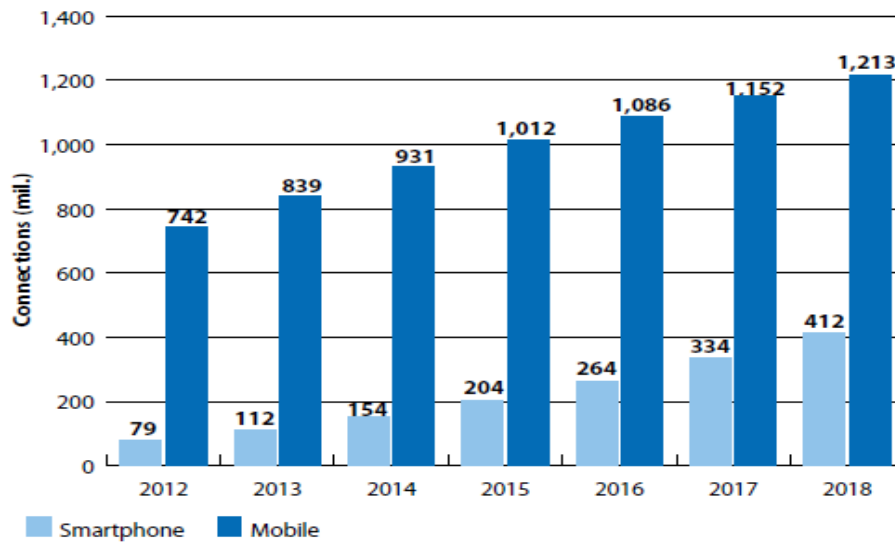


Figure 2: Africa Smart-Phone Connection Forecasts from 2012 to 2018 [27]

## 2. STATEMENT OF PROBLEM

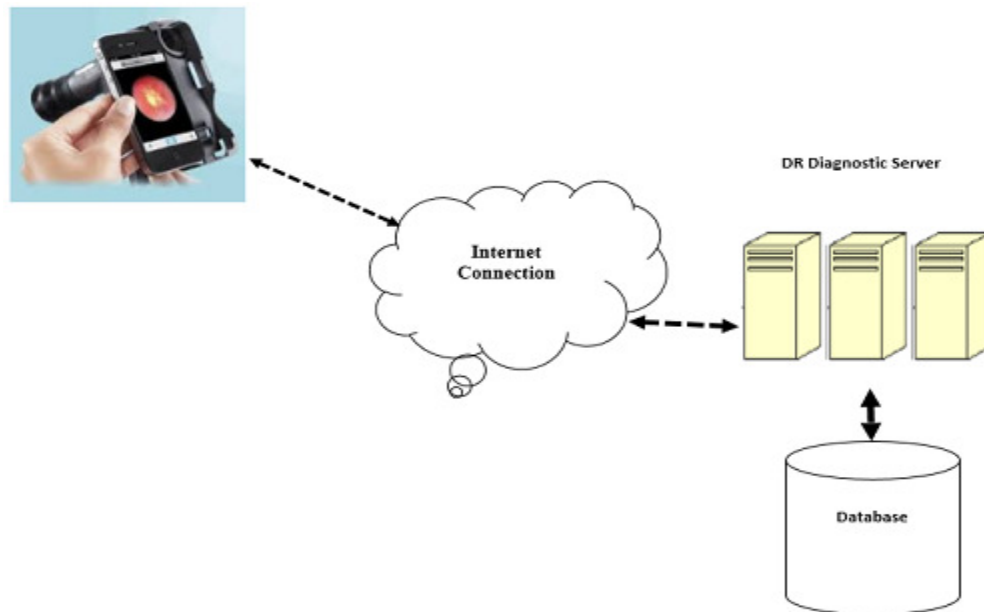
Regular examinations of retina can help in an early detection of DR and also significantly reduce the cases of blindness in diabetic patients. The implementation of distributed mobile health systems in cloud computing presents several advantages as it improves the work of health professionals [39]. As mobile technology rapidly make strides and smart-phones are also increasingly becoming affordable in Africa. According to Informa [27], there will be an increase in smart-phone connections in Africa from about 79 million at the end of 2012 to 412 million by 2018 (see Figure 2). As there are indications that there will be increase in the population of diabetic patients, the screening of large population of patients across the rural and urban areas can be time consuming, tedious and sometimes impossible due to the shortage of specialists. Smart-phone mobile-based diagnostic systems using automated approach has the potential to assists trained field workers in attending to larger number of people with diabetes in the rural and urban areas where there are no ophthalmologists [38]. This will yield a cost-effective and efficient early management of DR as patients who need further medical care can be referred to ophthalmologists at the early stage rather than advanced stage of the DR. There is also a need for secured a smart-phone image-based automated DR diagnostic system because the credibility of the system depends on its security.

## 3. OBJECTIVE

This paper presents the framework of a smart-phone image-based automated DR diagnostic system to improve the management of DR in Sub-Saharan Africa. A conceptual model that considers different security components that will help in securing the automated DR diagnostic system is also presented in this paper.

## 4. METHODOLOGY

The framework presented in this paper is built upon our previous studies on retinal vessel network detection in [23] [33] [34] [35] [37] [38] and vessel tortuosity measurement [36] [38]. Figure 3 shows the framework applied in this study while Figure 4 shows the different security components that will help in securing the proposed automated DR diagnostic system.



**Figure 3: Framework of a Smart-Phone Image-Based Automated DR Diagnostic System**

The framework consist of the client side, server side and communication channel. The client side consists of the smart-phone containing a fundus camera, graphical user interface (GUI), a program module and a cache. The coloured retinal fundus images captured using the smart-phone are stored on a database at the server side using the communication channel which is the internet connection. Different computational algorithms are applied at the server side to perform the detection of different retinal anatomic structures such as vessel networks and pathologies such as microaneurysms, exudates and cotton wool spot. The detected anatomic structures and pathologies of the retinal are stored on the database. The morphological features of the detected vessel networks are also analysed at the server side for the diagnosis and progress monitoring of the DR using different computational algorithms. The server has the capability to serve multiple clients concurrently. The internet connectivity also enables the users to view the detected anatomic structures and pathologies with the diagnosis results stored on the database in the server side using the GUI of the smart-phone.

## **5. SECURING THE SMART-PHONE IMAGE-BASED AUTOMATED DR DIAGNOSTIC SYSTEM**

An excellent approach is needed to secure the automated DR diagnostic system. This approach is a conceptual model that considers different security components. The proper understanding of the technical aspects of securing the retinal image data and the processed information on the server stored in the database requires that one knows the definitions of certain information technology terms and concepts. The security of data or information is often achieved by means of several strategies usually undertaken simultaneously or used in combination with one another.

- i. Confidentiality: Confidentiality of information is very important since it ensures that only those with sufficient privileges can access certain information. The confidentiality of a system is breached when unauthorized individuals or systems can access information. In order to protect the confidentiality of the medical information, information classification is put in place. The storage of the medical information storage should be properly secured while the users are educated on the issue of information confidentiality.
- ii. Integrity: Integrity is the quality or state of being whole, complete, and uncorrupted. The integrity of the DR diagnostic system is threatened when it is exposed to corruption, destruction, or disruption of the accurate state of the medical information.



- iii. Availability: Availability is the characteristic that enables the transfer of coloured fundus image from the client side or the response from the server without interference in the network availability. Network availability also means that the server is reachable by the authorized users.
- iv. Privacy: The DR patient's information collected, used, and stored is to be used only for the purposes stated to the patient at the time it was collected. This definition of privacy however means that information will be used only in ways known to the person providing it.
- v. Identification: Both the client side and the server side should possess the characteristic of identification when each smart-phone device and user are all recognized. As said, this applies to each smart-phone device and user. Identification and authentication are essential to establishing the level of access or authorization that an individual is granted.

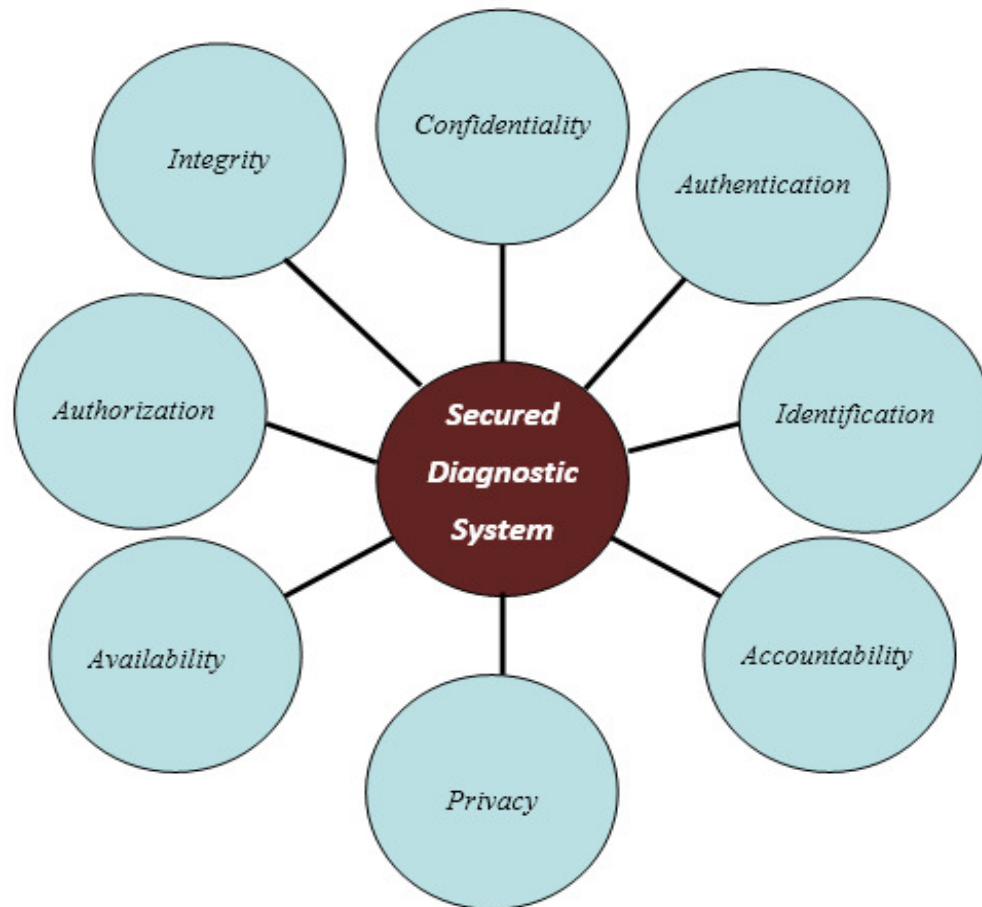


Figure 4: Security Approach for the Proposed DR Diagnostic System



- vi. Authentication: Authentication in the system occurs when a control provides proof that a user (i.e user of smart-phone and other legitimate users) possesses the identity that he or she claims on either the client side or server side.
- vii. Authorization: After the identity of a user is authenticated, a process called authorization provides assurance that the user (whether a person or a computer) has been specifically and explicitly authorized by the proper authority to access, and also perform some other functions on the system.
- viii. Accountability: The characteristic of accountability exists when a control provides assurance that every activity undertaken can be attributed to a named person, time or automated process. For example, audit logs that track user activity (user and patient) on the diagnostic system provide accountability.

## 6. CONCLUSION

This paper has discussed the smart-phone image-based automated DR Diagnostic system, its potentials for the management of DR in Africa and some security issues needed to be addressed. These security issues cannot be handled trivially but must be considered very important in the implementation of the smart-phone image-based automated DR Diagnostic system in Sub-Saharan Africa as it affects the credibility of the system and also has an impact on the confidence of the users. Our future shall investigate the different efficient methods of securing the smart-phone image-based automated DR Diagnostic system.



## REFERENCES

- [1] L. Ruta, D. Magliano, R. Lemesurier, H. Taylor, P. Zimmet, and J. Shaw, Prevalence of diabetic retinopathy in type 2 diabetes in developing and developed countries," *Diabetic Medicine*, vol. 30, no. 4, pp. 387-398, 2013.
- [2] I. D. Atlas, 6th edn," International Diabetes Federation. Brussels, Belgium, p. 160, 2013.
- [3] W. H. O., Action plan for the prevention of avoidable blindness and visual impairment, 2009-2013. World Health Organization, 2010.
- [4] J. W. Yau, S. L. Rogers, R. Kawasaki, E. L. Lamoureux, J. W. Kowalski, T. Bek, S.-J. Chen, J. M. Dekker, A. Fletcher, J. Grauslund et al., Global prevalence and major risk factors of diabetic retinopathy," *Diabetes care*, p. DC 111909, 2012.
- [5] A. M. Joussen, T. W. Gardner, and B. Kirchhof, *Retinal vascular disease* Springer, 2007.
- [6] E. Reichtman, A. Harris, H. J. Garzosi, and T. A. Ciulla, Pharmacologic therapies for diabetic retinopathy and diabetic macular edema," *Clinical ophthalmology (Auckland, NZ)*, vol. 1, no. 4, p. 383, 2007.
- [7] V. S. Joshi, Analysis of retinal vessel networks using quantitative descriptors of vascular morphology," Ph.D. Thesis, vol. 2012.
- [8] T. Mapayi, S. Viriri, and J.-R. Tapamo, Comparative study of retinal vessel segmentation based on global thresholding techniques," *Computational and Mathematical Methods in Medicine*, vol. 2015, no. Article ID 895267.
- [9] J. C. Mbanya, and E. Sobngwi. Diabetes microvascular and macrovascular disease in Africa. *European Journal of Cardiovascular Risk*, 10(2), 97-102, 2003.
- [10] E. H. Sidibe. [Main complications of diabetes mellitus in Africa]. In *Annales de medecine interne* (Vol. 151, No. 8, pp. 624-628), 2000.
- [11] N. S. Levitt, D. Bradshaw, M. F. Zwarenstein, A. A. Bawa, and S. Maphumolo, . Audit of public sector primary diabetes care in Cape Town, South Africa: high prevalence of complications, uncontrolled hyperglycaemia, and hypertension. *Diabetic Medicine*, 14(12), 1073-1077, 1997.
- [12] A. A. Motala, F. J. Pirie, E. Gouws, A. Amod, and M. A. Omar. Microvascular complications in South African patients with long-duration diabetes mellitus. *South African medical journal= Suid-Afrikaanse tydskrif vir geneeskunde*, 91(11), 987-992, 2001.
- [13] P. I. Burgess, G. Msukwa, and N. A. Beare. Diabetic retinopathy in sub-Saharan Africa: meeting the challenges of an emerging epidemic. *BMC medicine*, 11(1), 157, 2013.
- [14] C. Rotimi, H. Daniel, J. Zhou, A. Obisesan, G. Chen, Y. Chen, ... and G. Dunston. Prevalence and determinants of diabetic retinopathy and cataracts in West African type 2 diabetes patients. *Ethnicity and Disease*, 13(2; SUPP/2), S2-110, 2003.
- [15] D. Cantor-Rivera and T. Peters, Pervasive medical imaging applications Current challenges and possible alternatives," in Paper presented at IEEE Conference on E-Health, Networking, Application and Services, Lyon, 2010.
- [16] A. Rajaei and L. Rangarajan, Matching and retrieval of medical images," in International Symposium on Distributed Computing and Artificial Intelligence. Springer, 2011, pp. 27-33.
- [17] D. L. Pham, C. Xu, and J. L. Prince, Current methods in medical image segmentation 1," Annual review of biomedical engineering, vol. 2, no. 1, pp. 315-337, 2000.
- [18] C. Cuspidi and C. Sala, Retinal wall-to-lumen ratio: a new marker of endothelial function?" *Journal of hypertension*, vol. 29, no. 1, pp. 33-35, 2011.
- [19] M. D. Abr\_amo\_, M. K. Garvin, and M. Sonka, Retinal imaging and image analysis," *Biomedical Engineering, IEEE Reviews in*, vol. 3, pp. 169-208, 2010.
- [20] T. Mapayi, S. Viriri, and J.-R. Tapamo, Retinal vessel segmentation based on k-means clustering and difference image," in Proceedings of the 2014 Pattern Recognition Association of South Africa (PRASA), RobMech and AfLaT International Joint Symposium, Cape Town, South Africa, 2014, pp. 53-58.
- [21] J. Staal, M. D. Abr\_amo\_, M. Niemeijer, M. A. Viergever, and B. van Ginneken, Ridge-based vessel segmentation in color images of the retina," *Medical Imaging, IEEE Transactions on*, vol. 23, no. 4, pp. 501-509, 2004.



- [22] L. Verma, G. Prakash, and H. K. Tewari, Diabetic retinopathy: time for action. no complacency please!" BULLETIN-WORLD HEALTH ORGANIZATION, vol. 80, no. 5, pp. 419-419, 2002.
- [23] T. Mapayi, S. Viriri, and J.-R. Tapamo, Adaptive thresholding technique for retinal vessel segmentation based on glcm-energy information," Computational and mathematical methods in medicine, vol. 2015, 2015.
- [24] D. C. Klonoff and D. M. Schwartz, An economic analysis of interventions for diabetes." Diabetes care, vol. 23, no. 3, pp. 390-404, 2000.
- [25] Y. Yang and S. Huang, Image segmentation by fuzzy c-means clustering algorithm with a novel penalty term," Computing and Informatics, vol. 26, no. 1, pp. 17-31, 2012.
- [26] K. W. Tobin, E. Chaum, V. P. Govindasamy, and T. P. Karnowski, Detection of anatomic structures in human retinal imagery," Medical Imaging, IEEE Transactions on, vol. 26, no. 12, pp. 1729-1739, 2007.
- [27] Africa Telecoms Outlook 2014 - Informa Telecoms & Media. [http://files.informatandm.com/uploads/2013/11/Africa\\_Telecoms\\_Outlook\\_Low\\_resolution.pdf](http://files.informatandm.com/uploads/2013/11/Africa_Telecoms_Outlook_Low_resolution.pdf)
- [28] H. Li and O. Chutatape, Automated feature extraction in color retinal images by a model based approach," Biomedical Engineering, IEEE Transactions on, vol. 51, no. 2, pp. 246-254, 2004.
- [29] T. Walter and J.-C. Klein, Segmentation of color fundus images of the human retina: Detection of the optic disc and the vascular tree using morphological techniques," in Medical Data Analysis. Springer, 2001, pp.282-287.
- [30] D. Usher, M. Dumskyj, M. Himaga, T. Williamson, S. Nussey, and J. Boyce, Automated detection of diabetic retinopathy in digital retinal images: a tool for diabetic retinopathy screening," Diabetic Medicine, vol. 21, no. 1, pp. 84-90, 2004.
- [31] C. Sinthanayothin, J. Boyce, T. Williamson, H. Cook, E. Mensah, S. Lal, and D. Usher, Automated detection of diabetic retinopathy on digital fundus images," Diabetic Medicine, vol. 19, no. 2, pp. 105-112, 2002.
- [32] B. Wasan, A. Cerutti, S. Ford, and R. Marsh, Vascular network changes in the retina with age and hypertension." Journal of hypertension, vol. 13, no. 12, pp. 1724-1728, 1995.
- [33] T. Mapayi, S. Viriri, and J.-R. Tapamo, A new adaptive thresholding technique for retinal vessel segmentation based on local homogeneity information," in Image and Signal Processing. Springer, 2014, pp. 558-567.
- [34] T. Mapayi, J.-R. Tapamo and S. Viriri, Retinal Vessel Segmentation: A Comparative Study of Fuzzy C-means and Sum Entropy Information on Phase Congruency. International Journal of Advanced Robotic Systems, 12, 2015.
- [35] T. Mapayi, S. Viriri, and J.-R. Tapamo, Retinal vessel segmentation based on phase congruence and GLCM sum-entropy. In Industrial Technology (ICIT), 2015 IEEE International Conference on (pp. 1759-1764), 2015.
- [36] T. Mapayi, Detection and Characterisation of Retinal vessels. PhD Thesis, University of KwaZuluNatal 2015.
- [37] T. Mapayi, and J.-R. Tapamo, SAHF: Unsupervised Texture-Based Multiscale with Multicolor Method for Retinal Vessel Delineation. In *International Symposium on Visual Computing*, Springer, 2016, pp. 639-648.
- [38] T. Mapayi, J.R. Tapamo, S. Viriri, and A. Adio, Automatic retinal vessel detection and tortuosity measurement. *Image Analysis & Stereology*, 35(2), 2016, pp.117-135.
- [39] S.L. Albuquerque, and P.R. Gondim, Security in Cloud-Computing-Based Mobile Health. *IT Professional*, 18(3), 2016, pp.37-44.